

PennHIP Report

Referring Veterinarian: Dr Karen Taylor	Clinic Name: Animal Medical Center of Brooksville
Email: reception@animal-medical-center.com	Clinic Address: 22273 Cortez Blvd Brooksville, FL 34601
	Phone:
	Fax: (352) 796-1230

Patient Information

Client: Warfel, Victoria	Tattoo Num:
Patient Name: Owlbert	Patient ID: 5786
Reg. Name: Palisman of Hope	Registration Num: SS29378603
PennHIP Num: 192768	Microchip Num: 956000014149194
Species: Canine	Breed: GOLDEN RETRIEVER
Date of Birth: 19 Aug 2021	Age: 24 months
Sex: Male	Weight: 58.5 lbs/26.5 kgs
Date of Study: 21 Aug 2023	Date Submitted: 21 Aug 2023
Date of Report: 22 Aug 2023	

Findings

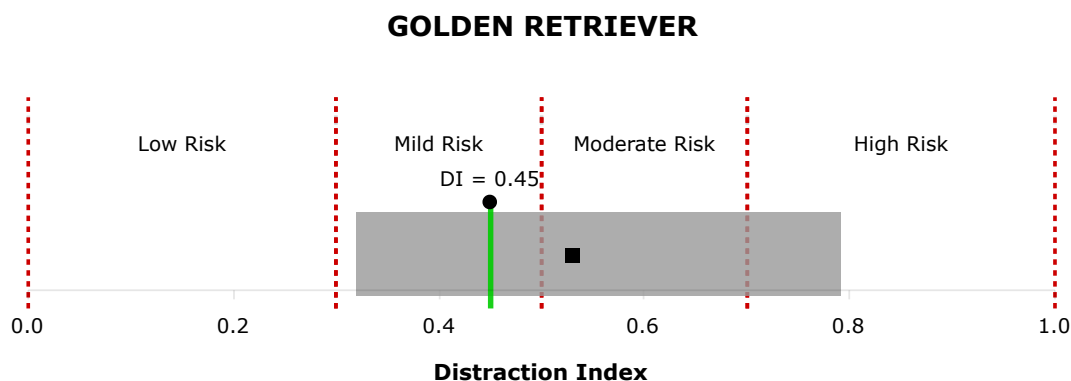
Distraction Index (DI): Right DI = 0.42, Left DI = 0.45.
Osteoarthritis (OA): No radiographic evidence of OA for either hip.
Cavitation/Other Findings: No cavitation present.

Interpretation

Distraction Index (DI): The laxity ranking is based on the hip with the greater laxity (larger DI). In this case the DI used is 0.45.

OA Risk Category: The DI is between 0.31 and 0.49. This patient is at mild risk for hip OA.

Distraction Index Chart:



BREED STATISTICS: This interpretation is based on a cross-section of 26170 canine patients of the GOLDEN RETRIEVER breed in the AIS PennHIP database. The gray strip represents the central 90% range of DIs (0.32 - 0.79) for the breed. The breed average DI is 0.53 (solid square). The patient DI is the solid circle (0.45).

SUMMARY: The degree of laxity (DI = 0.45) falls within the central 90% range of DIs for the breed. This amount of hip laxity places the hip at a mild risk to develop hip OA. **No radiographic evidence of OA for either hip.**